

# Analysis of intracranial volume ratios by means of cerebrospinal fluid deployment indicators

Ewa Szczepiek<sup>1,2</sup>, Leszek Tomasz Czerwosz<sup>3</sup>, Krzysztof Nowiński<sup>4</sup>, Zbigniew Czernicki<sup>1,2</sup>, Jerzy Jurkiewicz<sup>1</sup>

<sup>1</sup>Department of Neurosurgery, Second Faculty of Medicine, Medical University of Warsaw, <sup>2</sup>Department of Neurosurgery, Mossakowski Medical Research Centre, Polish Academy of Sciences, Warsaw, <sup>3</sup>Mossakowski Medical Research Centre, Polish Academy of Sciences, Warsaw, <sup>4</sup>Interdisciplinary Centre for Mathematical and Computational Modelling of the University of Warsaw, Warsaw, Poland

Folia Neuropathol 2015; 53 (2): 121-127

DOI: 10.5114/fn.2015.52408

## Abstract

**Introduction:** Imaging studies make it possible not only to visualize the general structure of the brain but also to take precise measurements of brain tissue volume and the size of individual lobes and their structure. The aim of this study was to determine the ratio of cerebrospinal fluid (CSF) volume contained in the intracranial ventricular system to the brain tissue volume and the ratio of CSF volume in the subarachnoid space and basal cisterns to the brain tissue volume.

**Material and methods:** The evaluation of volumetric measurements of computed tomographic (CT) images was undertaken on 23 male and female patients (average age  $56.9 \pm 6.1$ ) diagnosed with normal pressure hydrocephalus (NPH) and 27 male and female patients (average age  $70.6 \pm 5.2$ ) diagnosed with brain atrophy (BA). In the CT imaging studies, the total brain tissue volume and CSF volume collected in the intracranial fluid cavities were mapped to a colour scale. The VisNow software was used for volumetric evaluation. The groups were compared by means of the non-parametric Kolmogorov-Smirnov test (K-S) for independent samples. Paired data were compared by means of the nonparametric Wilcoxon test.

**Results:** The volumes of brain (brain volume – BV) and cerebrospinal fluid (fluid volume – FV) differ greatly from each other in both groups BA and NPH. The SBR (subarachnoid space and basal cisterns-to-brain ratio) and VBR (ventricle-to-brain ratio) indicators differ significantly and very much within the NPH group as well as within the BA group. In the NPH group a clearly higher value of VBR can be observed in comparison with the BA group. There was a higher value of SBR in the BA than the NPH group.

**Conclusions:** The simultaneous use of two indicators, VBR and SBR, on a study group of 50 patients enabled the total separation of NPH and BA groups. This differentiation can have real diagnostic value. Thus the volumetric assessment of the volume of CSF and brain tissue based on CT of the head can become an important part of the differential diagnosis of hydrocephalus and brain atrophy.

**Key words:** volumetry, hydrocephalus, brain atrophy.

## Introduction

Advances in the diagnostics of central nervous system (CNS) disorders are connected to a large degree with radiological assessment – the analysis

of computed tomographic (CT) and magnetic resonance (MRI) images. The largest application is for head examinations, especially the brain. Imaging studies make it possible not only to visualize the general

## Communicating author:

Dr Leszek Tomasz Czerwosz, Mossakowski Medical Research Centre, Polish Academy of Sciences, 5 Pawińskiego St., 02-106 Warsaw, Poland, e-mail: czerwosz@imdik.pan.pl

structure of the brain, but also to make precise measurements of brain tissue volume, of the size of individual lobes and their structure (volumetry) [7,15]. The application of specialist software for the analysis of CT and MRI images has made it possible to perform volumetric examinations to obtain non-invasive volume measurements of specific intracranial compartments (i.e., the volume of cerebrospinal fluid [CSF] contained in the subarachnoid space and basal cisterns, in the intracranial ventricular system and the brain tissue volume).

This has been found to be an important clinical application for the non-invasive diagnosis of normal pressure hydrocephalus and various types of brain atrophy. The ageing of society is clearly noticeable in recent years, and the lengthening of life has meant that diseases associated with dementia, the prevalence of which increases with age, currently represent a serious medical and social problem. For this reason, the possibility of early detection of disorders associated with dementia, their diagnosis and differentiation from the symptoms of the development of normal pressure hydrocephalus are of significant importance.

To achieve the intended aim, imaging studies, including CT and MRI volumetric examinations, have made it possible to precisely estimate the volume of the intracranial components of the CNS [16].

From the point of view of differential diagnosis on the basis of CT or MRI studies, we define the intracranial contents as the brain volume and the volume of CSF contained in the intracranial ventricular system and in the subarachnoid space and basal cisterns. According to data from the literature [11], the average brain volume of a healthy person is 1400 cm<sup>3</sup> and the average CSF volume is 140 cm<sup>3</sup>.

Difficulty in the diagnosis of normal pressure hydrocephalus (NPH) and differentiating it from brain atrophy (BA) means that normal pressure hydrocephalus is diagnosed in a large percentage of cases that were in fact brain atrophy. It is also possible that brain atrophy is diagnosed in those cases that were in fact hydrocephalus. The commonly applied invasive diagnostic procedure is the infusion test [8], which gives the highest probability of correct diagnosis. This result should always be interpreted together with non-invasive diagnostic procedures, such as neurological examinations, neuropsychological examinations [9], motor and posture parameters [5,6,12],

evoked potential, and particularly with CT and/or MRI brain imaging [4].

The Visual Analysis group co-chaired by Dr. Krzysztof Nowiński from the Interdisciplinary Centre for Mathematical and Computational Modelling at the University of Warsaw (ICM) has developed special software, VisNow [14], for the visual analysis of data, in particular for the analysis of a three-dimensional tissue density matrix, which is the result of computed tomography. The software allows not only visualization but also spatial morphometric calculations of tissue density specified in Hounsfield units. Szczeppek *et al.* [13] used the VisNow tool for volumetric evaluation of CSF distribution in the intracranial fluid compartments in hydrocephalus and brain atrophy. The real absolute value (in cm<sup>3</sup>) of the CSF voxels contained in the subarachnoid space and basal cisterns and in the intracranial ventricular system space was determined. The accuracy of volumetric outcomes has been compared to the planimetry paper of Marszałek *et al.* [9]. Szczeppek relied solely on small groups of patients with normal pressure hydrocephalus and with brain atrophy. For both groups the mean value of the volume of CSF in the subarachnoid space and basal cisterns differs at a level of statistical significance from the mean value of CSF volume of normal healthy people. It has also been shown that the ratio of volume of CSF in the ventricles to the volume of CSF in the subarachnoid space and basal cisterns is an important diagnostic indicator for differentiating NPH from brain atrophy.

The aim of this study is to determine the ratio of the intracranial CSF to the brain tissue volume, the volume of CSF contained in the intracranial ventricular system to the brain volume and the volume of CSF in the subarachnoid space and basal cisterns to brain volume.

The aim of the analysis of this study is to answer the question of the clinical relevance of the above-mentioned indicators:

- to determine the proportion of the pathologies under study,
- to make it possible to differentiate normal pressure hydrocephalus from brain atrophy with the aid of the abovementioned indicators.

## Material and methods

At this neurosurgical clinic, an evaluation of the volumetric measurements of CT images was under-

taken in 23 male and female patients (average age  $56.9 \pm 6.1$ ) with a diagnosis of normal pressure hydrocephalus and in 27 male and female patients (average age  $70.6 \pm 5.2$ ) with a diagnosis of brain atrophy. In the CT imaging studies, the total brain tissue volume and the volume of CSF collected in the intracranial fluid compartments were mapped.

The study was undertaken in accordance with the Helsinki Declaration after obtaining the prior agreement of the Bioethical Committee of the Warsaw Medical University. The clinical criteria for the diagnosis of normal pressure hydrocephalus were established based on the following: dilatation of the ventricular system in CT or MRI studies; the Evans indicator with a value  $> 0.3$ ; the lack of or little evidence of cortical atrophy; Hakim's triad – at least two symptoms; the value of intracranial pressure measured with the aid of a lumbar puncture  $NL \geq 10$  cmH<sub>2</sub>O; resorption resistance  $R \geq 11$  mmHg/ml/min; and a neuropsychological assessment.

The diagnosis of brain atrophy was established on the basis of the following symptoms: dilatation of the ventricular system in CT or MRI studies of the head; the Evans indicator with a value  $\leq 0.3$ ; evidence of cortical and corticobasal atrophy; neurological symptoms; the value of intracranial pressure measured during a lumbar puncture  $NL < 10$  cmH<sub>2</sub>O; resorption resistance  $R < 11$  mmHg/ml/min; and a neuropsychological assessment.

The results of the neurological examination were maintained in accordance with the set of tests developed and currently applied in this clinic [9].

Volumetric evaluation using the VisNow software, developed from scratch in ICM for volumetric evaluation, is an impartial, quantitative, statistical method for measuring the voxel characteristics in selected CNS regions. The technical data of the software were published by Szczepek *et al.* in 2015 [13]. A statistical analysis of the voxels was undertaken for the brain tissue volume and the total volume of CSF contained in the intracranial fluid compartments.

In this study, the statistical analysis was based on the volume of the subarachnoid space and basal cisterns, the volume of the intracranial ventricular system and also on the brain tissue volume (BV) in the CT imaging studies of the head (performed at intervals no longer than two months) in patients classified in the group of hydrocephalus and brain atrophy. Total CSF volume (FV) was the sum of the

subarachnoid space and basal cisterns and the volume of the intracranial ventricular system.

The following indicators were established:

- VBR (ventricle-to-brain ratio) (expressed as a fraction) – the ratio of the volume of the CSF in the intracranial ventricular system to the brain volume;
- SBR (subarachnoid space and basal cisterns-to-brain ratio) (expressed as a fraction) – the ratio of the volume of CSF in the subarachnoid space and basal cisterns to the brain volume.

The groups were compared by means of the non-parametric Kolmogorov-Smirnov test (K-S) for independent samples. Dependent samples were compared by means of the nonparametric Wilcoxon test.

## Results

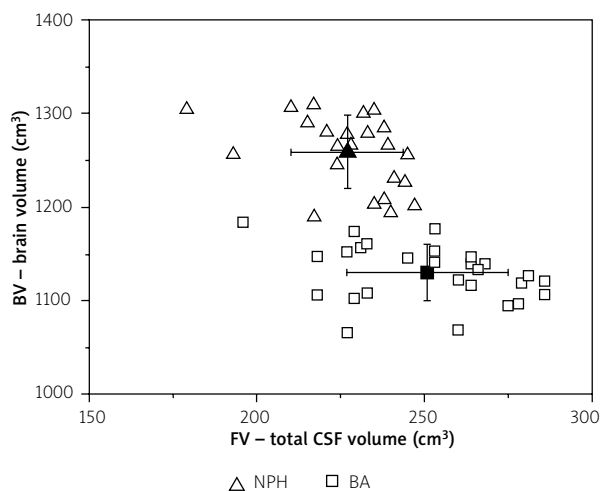
The results of the statistical analysis (Kolmogorov-Smirnov) for the two groups – normal pressure hydrocephalus (NPH) and brain atrophy (BA) groups – showed that the brain volumes (BV) are different at a statistically significant level in these groups (Table I). The total volumes of CSF (FV) in the intracranial fluid compartments (CSF contained in the subarachnoid space and basal cisterns as well as the intracranial ventricular system) differ in these groups as well. The volumes of BV and FV differ greatly from each other in both groups; there is no need for a statistical test in this case.

A scatter plot of the value of BV and FV together with the mean values of the BA and NPH groups is shown in Figure 1.

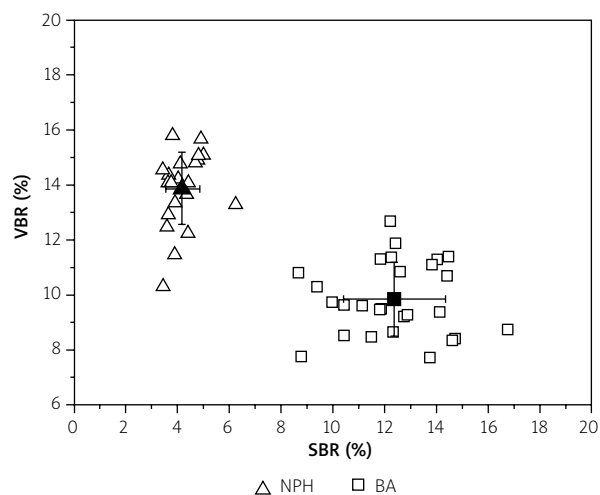
A statistical evaluation for the measurements of the mean values of VBR and SBR indicators in patients with normal pressure hydrocephalus and brain atrophy are presented in Table II. Comparisons

**Table I.** Mean value and standard deviation of the brain volume (BV) and total cerebrospinal fluid (CSF) volume (FV) in the groups of patients with normal pressure hydrocephalus (NPH) and brain atrophy (BA). The NPH and BA groups are compared by means of the Kolmogorov-Smirnov test. Z statistics and exact probability are given

Group	BV (cm <sup>3</sup> )	FV (cm <sup>3</sup> )
NPH (23)	1258 ± 39	227 ± 17
BA (27)	1130 ± 14	251 ± 24
Comparison of NPH-BA: K-S Z value and exact prob.	Z = 0.28 $p = 1.8 * 10^{-14}$	Z = 0.16 $p = 0.00012$



**Fig. 1.** A scatter plot of individual values of brain volume (BV) and volumes of cerebrospinal fluid (CSF) contained in the subarachnoid space and basal cisterns and also in the intracranial ventricular system (FV) in patients with normal pressure hydrocephalus (NPH) and brain atrophy (BA). The mean volumes with standard deviations of BA and NPH groups are plotted in the same coordinate system.



**Fig. 2.** A scatter plot of individual values of VBR (ventricle-to-brain ratio) and SBR (subarachnoid space and basal cisterns-to-brain ratio) indicators in patients with normal pressure hydrocephalus (NPH) and brain atrophy (BA). The mean volumes with standard deviations of BA and NPH groups are plotted in the same coordinate system.

of two groups are presented for VBR and SBR independently.

The results of the statistical analysis (Wilcoxon test) for dependent variables proved that SBR and VBR indicators differ significantly and very much within the NPH group as well as within the BA group (Table II).

In the patients classified as the normal pressure hydrocephalus group, a clearly higher value of the VBR can be observed in comparison with patients

classified as the brain atrophy group. Analysing the SBR indicator, it was found that there was a higher value of SBR in the group of patients with a diagnosis of brain atrophy than in the group of patients with normal pressure hydrocephalus. There is a very low probability of erroneous outcome of statistical tests (less than  $10^{-12}$ ).

A scatter plot of individual VBR and SBR indicators together with the mean values of BA and NPH groups is shown in Figure 2. One can observe

**Table II.** Mean value and standard deviation of the indicators FBR (fluid-to-brain ratio), VBR (ventricle-to-brain ratio) and SBR (subarachnoid space and basal cisterns-to-brain ratio) in the groups of patients with normal pressure hydrocephalus (NPH) and brain atrophy (BA). NPH and BA groups are compared by means of the Kolmogorov-Smirnov test. Z statistics and exact probability are given. The Wilcoxon probability was calculated for independent comparisons of VBR and SBR indicators within the BA and NPH groups

Group	VBR (%)	SBR (%)	Comparison of VBR-SBR Wilcoxon probability
NPH (23)	13.9 ± 1.3	4.2 ± 0.7	$p < 2.4 \times 10^{-7}$
BA (27)	9.9 ± 1.3	12.4 ± 2.0	$p < 6.4 \times 10^{-6}$
Comparison of NPH-BA: K-S Z value and exact probability	Z = 0.27 $p < 4.4 \times 10^{-13}$	Z = 0.28 $p < 1.8 \times 10^{-14}$	–

a wide gap between the BA and NPH groups. This observation is consistent with the results of statistical tests.

## Discussion

The variety of diagnostic procedures for differentiating normal pressure hydrocephalus and brain atrophy is proof of the difficulty in differentiating the two pathological syndromes. In spite of the fact that invasive procedures carry a risk of development of complications, they are still necessary in the diagnosis of hydrocephalus. For this reason, we attempted to develop a non-invasive differential diagnostic procedure for normal pressure hydrocephalus and brain atrophy. The presented observations are a further attempt to introduce into clinical practice a non-invasive diagnostic procedure – the evaluation of intracranial volumetric indicators of the distribution of the volume of CSF and brain tissue volume.

The volumetric evaluation undertaken in this study using CT imaging studies of the head showed that there were changes in the distribution of the volume of CSF and brain tissue volume in the intracranial compartments of the CNS for both hydrocephalus (NPH) and BA groups of patients. The scope of these changes differed in each particular group.

The new indicators VBR and SBR, identified in the study, made it possible to estimate the value of the volume of CSF in relation to the brain tissue volume in specific intracranial spaces of the CNS in the groups of patients with NPH and BA.

The results obtained in our study are similar to the results obtained by Blatter *et al.* [3]. The authors presented a quantitative evaluation of the volumetric intracranial parameters of volume ratios using MRI imaging studies in a control group. One hundred ninety-four healthy persons, including men and women in the age range from 16 to 65 years old, were divided into five ten-year age groups. The analysis included the total volume of CSF in the intracranial ventricular system and in the subarachnoid space, the total brain volume and the total intracranial volume.

A highly significant change was noticed with age. The authors found that the mean brain volume decreases with age, and the smallest value of brain volume was noted in the 5<sup>th</sup> decade of life (56-65 years old). The mean volume of CSF increases

with age, and the highest value of CSF volume was recorded in the 5<sup>th</sup> decade of life (56-65 years old).

In the abovementioned study, in the group of healthy persons, the VBR indicator was also identified – the ratio of the volume of CSF in the intracranial ventricular system to the total brain volume. In healthy people in the age range of 56-65 years, the VBR for women was  $2.08 \pm 1.11$  and for men  $2.07 \pm 0.88$ . The presented range of the VBR index in the control group in the specified age range should be compared with the VBR results obtained in our publication. It can also be noted that the value of VBR obtained in our study clearly differs from the norms in both of the discussed CNS pathologies. In our study, the VBR coefficient in the BA group ( $9.9 \pm 1.3$ ) is at a lower level than in the volumetric studies of the NPH group ( $13.9 \pm 1.3$ ). An explanation for this could be that in the BA group loss of brain tissue (i.e., brain volume) occurs with increasing age and with the progression of atrophy of the neural pathways. It should be noted that the CSF distribution in the intracranial fluid compartments is different in the group of patients with BA than in the group with NPH. It was observed that a higher value of CSF in the intracranial ventricular system was obtained in the patients with NPH, whereas a higher value of CSF in the subarachnoid space was obtained with patients diagnosed with BA.

The use of volumetric evaluation for tracking the volume changes in the intracranial compartments of the CNS in neurodegenerative disorders is also found in the study by Bigler *et al.* [2]. The authors performed an analysis of the volume parameters in patients with various types of dementia over the age of 65 years (i.e., Alzheimer's disease, vascular dementia). The VBR coefficient was identified. The results of the volumetric parameters presented by the authors in the study in patients with Alzheimer's disease or with vascular dementia are similar to the results of the study obtained in our publication with patients classified to the group of brain atrophy – a reduction in brain volume and an increase in the volume of CSF in the intracranial fluid compartments.

Akdogan *et al.* [1] undertook to use volumetric evaluation to highlight the relationship between TVV (total ventricle volume) and TBV (total brain volume). For their analysis, 40 men (average age  $40.9 \pm 3.7$  years) and 40 women (average age  $41.4 \pm 3.6$  years) were selected. Patients were excluded from

the study if a CT imaging study of the head presented intracranial bleeding or traumatic brain injury. It was found that the ratio TVV/TBV in the group of patients in the first decade was only 1.27%, whereas for the group of patients in the third decade the ratio rose to as much as 3.37%. The results were connected with increasing volume of CSF in the intracranial ventricular system and with decreasing brain volume together with age and the associated ageing process of the brain.

The authors observed that the volume ratio TVV/TBV turned out to be an important indicator for diseases, i.e., hydrocephalus, Alzheimer's, and disorders of a neurodegenerative nature.

In the study of Nestor *et al.* [10], semi-automatic software was presented that enabled the volumetric evaluation of MRI imaging studies for the early detection of dementia disorders. The authors found that the volume of CSF in the intracranial ventricular system can constitute an explanation for Alzheimer's disease or mild cognitive impairments. In the analysed group of patients, the volume of CSF in the brain ventricles was evaluated at an early stage of the illness and after 6 months for control purposes. It was noticed that patients with a diagnosis of Alzheimer's have clearly a larger volume of the ventricles than is the case in the group of patients with mild cognitive impairments. In Nestor's study, the possibility of evaluating the progression of changes of the volume ratios was also mentioned (i.e., a clear increase of the volume in the intracranial ventricular system was noted after 6 months in patients with mild cognitive impairments).

The results obtained in Nestor's study concur with the data from the literature. It should be underlined at this point that all of the abovementioned indicators can be used with success for the evaluation of the development of intracranial pathologies, but they do not give an unambiguous answer whether a specific examined case should be classified as brain atrophy or as hydrocephalus. For differentiating these pathological processes, the best indicator is in our opinion [13] an indicator highlighting the ratio of the volume of CSF in the brain ventricles to the volume of CSF contained in the subarachnoid space and basal cisterns.

It should be emphasized that the simultaneous use of the two indicators VBR and SBR on a study group of 50 patients enabled the total separation of NPH and BA groups. This differentiation can have real

diagnostic value. Thus the volumetric assessment of the volume of CSF and brain tissue based on CT of the head can become an important part of the differential diagnosis of hydrocephalus and brain atrophy.

## Acknowledgments

The research support was partially provided by the project POIG.02.03.00-00-003/09 "Applications of digital technologies in medicine", which was carried out based on a common project of the Polish Academy of Sciences research institutions – "Bio-centrum Ochota – information infrastructure for the strategic areas of biology and medicine".

## Disclosure

Authors report no conflict of interest.

## References

1. Akdogan I, Kiroglu Y, Onur S, Karabulut N. The volume fraction of brain ventricles to total brain volume: a computed tomography stereological study. *Folia Morphologica* 2010; 69: 193-200.
2. Bigler ED, Lowry CM, Anderson CV, Johnson SC, Terry J, Steed M. Dementia, quantitative neuroimaging and apolipoprotein E genotype. *AJNR Am J Neuroradiol* 2000; 21: 1857-1868.
3. Blatter DD, Bigler ED, Gale SD, Johnson SC, Anderson CV, Burnett BM, Parker N, Kurth S, Horn SD. Quantitative volumetric analysis of brain MR: normative database spanning 5 decades of life. *AJNR Am J Neuroradiol* 1995; 16: 241-251.
4. Czernicki Z, Walecki J, Jurkiewicz J, Grochowski W, Tychmanowicz K. Intracranial volume reserve determination using CT images, numerical analysis and lumbar infusion tests. An experimental study. *Acta Neurochir* 1992; 115: 43-46.
5. Czerwosz L, Szczepek E. Hydrocephalus. In: Recognition of Posture and Gait Disturbances in Patients with Normal Pressure Hydrocephalus Using a Posturography and Computer Dynography Systems. Czerwosz L, Szczepek E, Sokołowska B, Jurkiewicz J, Czernicki Z. *InTech* 2012; 12, pp. 189-214.
6. Czerwosz L, Szczepek E, Sokołowska B, Jurkiewicz J, Czernicki Z. Posturography in differential diagnosis of normal pressure hydrocephalus and brain atrophy. *Adv Exp Med Biol* 2013; 755: 311-324.
7. Duning T, Kloska S, Steinsträter O, Kugel H, Heindel W, Knecht S. Dehydration complicates the assessment of brain atrophy. *Neurology* 2005; 64: 876-879.
8. Juniewicz H, Kasprówicz M, Czosnyka M, Czosnyka Z, Gizewski S, Dzik M, Pickard JD. Analysis of intracranial pressure during and after the infusion test in patients with communicating hydrocephalus. *Physiol Meas* 2005; 26: 1039-1048.
9. Marszałek P, Jurkiewicz J, Fersten E, Luczywek E, Czernicki Z, Gielecki J, Bogucki J. Multi-stage method for the diagnosis of low-pressure hydrocephalus. *Neurol Neurochir Pol* 1997; 31: 527-539.

10. Nestor SM, Rupsingh R, Borrie M, Smith M, Accomazzi V, Wells JL, Fogarty J, Bartha R; Alzheimer's Disease Neuroimaging Initiative. Ventricular enlargement as a possible measure of Alzheimer's disease progression validated using the Alzheimer's disease neuroimaging initiative database. *Brain* 2008; 131: 2443-2454.
11. Rengachary SS, Ellenbogen RG. *Principles of Neurosurgery*. Elsevier Mosby, Edinburgh 2005; pp. 99-115.
12. Szczepek E, Czerwos L, Dąbrowski P, Dudziński K, Jurkiewicz J, Czernicki Z. Posturography and computerized gait analysis in the Computer Dyno Graphy system as non-invasive methods for evaluation of normal pressure hydrocephalus progression. *Neurol Neurochir Pol* 2008; 42: 139-152.
13. Szczepek E, Czerwos L, Nowiński K, Jurkiewicz J, Czernicki Z. Evaluation of volumetric changes in differential diagnosis of brain atrophy and active hydrocephalus. *Adv Exp Med Biol* 2015; 840: 59-67.
14. VisNow visualization software developed at Laboratory of Visual Analysis at Interdisciplinary Center of Mathematical and Computational Modeling (2011). <http://visnow.icm.edu.pl>. Accessed 18 Apr 2015.
15. Walecki J, Ziemiański A. *Magnetic Resonance Imaging and Computed Tomography in clinical practice*. Springer PWN, Warsaw 1997; pp. 215-225.
16. Whitwell JL, Crum WR, Watt HC, Fox NC. Normalization of cerebral volumes by use of intracranial volume: implications for longitudinal quantitative MR imaging. *AJNR Am J Neuroradiol* 2001; 22: 1483-1489.